

Baptist Health South Florida

Scholarly Commons @ Baptist Health South Florida

All Publications

4-1-2021

Use of the Purse-String Suture to Conservatively Manage a Cornual Ectopic Pregnancy

Jose Castaneda

Bethesda Hospital East, pepecastanedamd@yahoo.com

Follow this and additional works at: <https://scholarlycommons.baptisthealth.net/se-all-publications>

Citation

Cureus (2021) 13(4):e14249

This Article -- Open Access is brought to you for free and open access by Scholarly Commons @ Baptist Health South Florida. It has been accepted for inclusion in All Publications by an authorized administrator of Scholarly Commons @ Baptist Health South Florida. For more information, please contact Carrief@baptisthealth.net.

Use of the Purse-String Suture to Conservatively Manage a Cornual Ectopic Pregnancy

Oluwatofunmi Oshodi¹, Jose Castaneda²

1. Obstetrics and Gynecology, Florida Atlantic University Charles E. Schmidt College of Medicine, Boca Raton, USA 2. Obstetrics and Gynecology, Bethesda Hospital East, Boynton Beach, USA

Corresponding author: Oluwatofunmi Oshodi, tofunmioshodi@gmail.com

Abstract

We report the successful management of a 31-year-old female, treated by cornual wedge resection. The patient suffered from vaginal spotting and lower abdominal pain. Transvaginal ultrasonography revealed a 4-5 cm right cornual pregnancy and beta-human chorionic gonadotropin was measured to be 614.7 IU/L. This ectopic pregnancy was removed via a laparotomy with cornual wedge resection and right salpingectomy.

Categories: Emergency Medicine, Obstetrics/Gynecology

Keywords: ectopic pregnancy, cornual pregnancy, salpingectomy, tubal pregnancy, vaginal spotting

Introduction

Cornual (interstitial) pregnancy is a rare form of ectopic pregnancy and accounts for only 2%-4% of all tubal pregnancies, yet has a maternal mortality of 2%-2.5% [1]. A cornual pregnancy is a pregnancy that is implanted in the proximal part of the fallopian tube, lying with the muscular wall of the uterus [2]. This section of the fallopian tube is thick and highly vascularized; thus, rupture presents later and with more severe bleeding compared to those of other ectopic pregnancies, leading to catastrophic hemorrhage [3]. The typical rupture of cornual pregnancies usually occurs later than nine weeks and can occur as late as 20 weeks [4]. The mortality rate for a cornual pregnancy is seven times greater than that of other forms of ectopic pregnancy [5]. Risk factors for cornual pregnancy include history of ectopic pregnancy, rudimentary horn, in vitro fertilization, and ipsilateral salpingectomy [1,6]. Clinical findings specific for ectopic pregnancy include the absence of an intrauterine gestational sac and beta-human chorionic gonadotropin (hCG) levels higher than 1,500 mIU per mL [7]. Transvaginal ultrasound (TVUS) has been the mainstay tool used to diagnose interstitial pregnancies (IPs), while MRI may be used in patients who are clinically stable and whose diagnosis remains unclear despite having a TVUS. Historically, IPs have been managed with the use of wedge resection by either laparoscopic or open surgery. Hysterectomies have also been used to manage IPs [8]. Current management of cornual pregnancies is less invasive, and centered on limiting hemorrhage and improving long-term fertility and obstetric outcomes. We report a case of a 31-year-old woman, who was diagnosed preoperatively with a cornual pregnancy via TVUS and a positive beta-hCG. This ectopic pregnancy was removed via a laparotomy with cornual wedge resection and right salpingectomy. The encircling suture method was used to remove the ectopic pregnancy, which has been shown to be simple, safe, effective, and nearly bloodless [9].

Case Presentation

This is a case of a 31-year-old Hispanic female, gravida 4 para 0 aborta 3, at five weeks gestation with no significant past medical history, who presented to the emergency department (ED) after her initial prenatal visit revealed the possible presence of a cornual pregnancy on ultrasound (Figure 1). Her physician sent her to the ED for an emergent removal of the ectopic pregnancy. Her chief complaint was vaginal spotting and lower abdominal pain for the duration of one day. Clinically, the patient appeared hemodynamically stable, with a heart rate of 81 bpm and blood pressure of 130/81. Quantitative beta-hCG was 614.7 and TVUS revealed an anteverted uterus that appears grossly homogeneous. Endometrial stripe measured up to 7 mm in thickness with no gestational sac noted within the midline uterine fundus or body. In the right adnexa there was a 4.9 x 4.2 x 2.2 cm thick rind from the ovary. The location and appearance were concerning for a cornual pregnancy/IP given the positive beta-hCG and empty uterine cavity. The right ovary measured approximately 3.5 x 2.1 x 2.8 cm and contained a simple follicle. The left ovary measured 2.9 x 1.5 x 1.4 cm and appeared grossly normal. No pelvic free fluid was identified. The patient underwent emergency removal of the ectopic pregnancy.

Review began 02/02/2021

Review ended 03/27/2021

Published 04/01/2021

© Copyright 2021

Oshodi et al. This is an open access article distributed under the terms of the Creative Commons Attribution License CC-BY 4.0., which permits unrestricted use, distribution, and reproduction in any medium, provided the original author and source are credited.

How to cite this article

Oshodi O, Castaneda J (April 01, 2021) Use of the Purse-String Suture to Conservatively Manage a Cornual Ectopic Pregnancy . Cureus 13(4): e14249. DOI 10.7759/cureus.14249

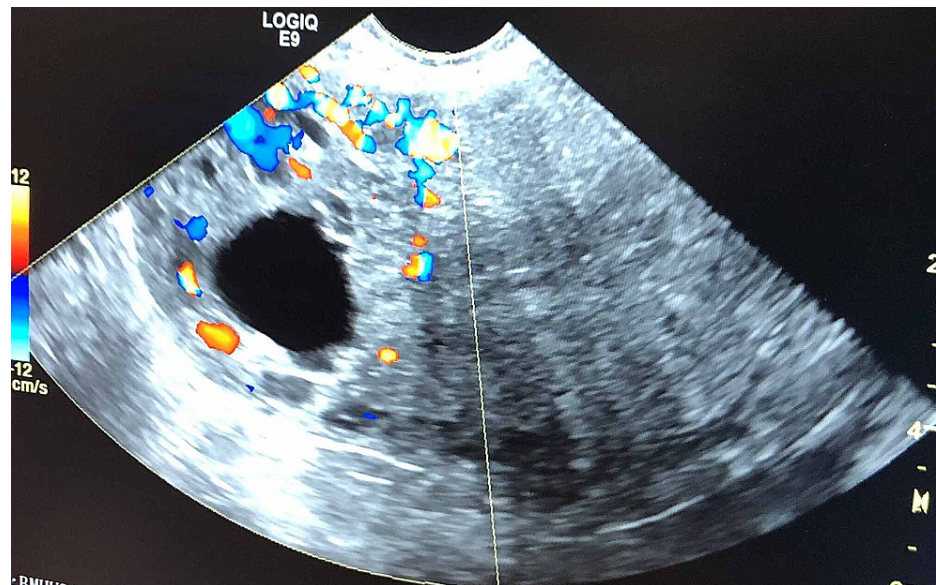


FIGURE 1: An ultrasound image of the cornual pregnancy

Treatment and follow-up

We identified a 4-5 cm cornual ectopic pregnancy (Figure 2). The fimbria and round ligament were cut on the right side, completing a total right salpingectomy to avoid recurrence, and a vicryl zero suture was put in the upper part of the uterine artery three times for hemostasis. Another suture was put in medially, followed by another suture anteriorly and posteriorly in the uterine wall, around the base ectopic pregnancy. The cornual was incised and the conceptus was extracted using an encircling suture around the base of the cornual pregnancy (Figure 2A). The encircling suture was tied to produce a tourniquet effect. While tension was kept on the knot, electric cauterization was used to incise the cornua and remove the conceptus. This procedure of using encircling sutures to produce a tourniquet around the ectopic pregnancy leads to secure hemostasis. The patient's estimated blood loss was less than 75 mL. It is routine that after surgery, hCG should be measured multiple times at different time periods to ensure the efficacy of the therapy. On post-operative day 2, her quantitative beta-hCG was measured to be 65.9 IU/L. Patient followed up with her provider for post-operative visits and quantitative beta-hCG measurements.

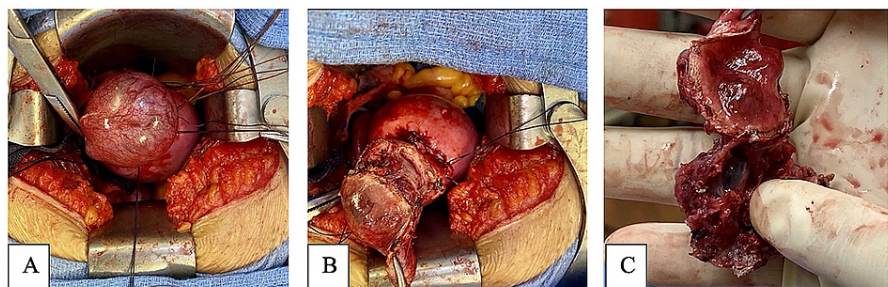


FIGURE 2: Tourniquet purse suture around right cornual mass (A), incising the mass (B), mass after excision (C)

Discussion

Cornual pregnancies represent 2%-4% of all ectopic pregnancies [1]. The three diagnostic criteria for cornual pregnancy described by Timor-Tritsch et al. include (1) an empty uterine cavity, (2) a chorionic sac seen separately and >1 cm from the most lateral edge of the uterine cavity, and (3) a thin myometrial layer surrounding the gestational sac [10]. The findings of our patient were consistent with all of these criteria. Rupture of a cornual pregnancy may result in intra-abdominal bleeding, hence the urgency of treatment. However, treatment of this clinical presentation still raises the concern of severe hemorrhage due to the highly vascularized region of cornual pregnancies and later time of diagnosis [3]. Management of a cornual pregnancy is dependent on the size of the ectopic pregnancy. A cornual pregnancy of medium size (<5 cm) can be managed conservatively with methotrexate if there are no contraindications, such as intra-abdominal

bleeding and concomitant intrauterine pregnancy. However, treatment with methotrexate has been associated with a failure rate as high as 65% [1,8,11,12,13]. Large cornual pregnancies of 5 cm or larger should be managed surgically due to increased risk of rupture. This patient's cornual pregnancy of 4-5 cm was concerning for rupture and thus was managed surgically through the use of a tourniquet purse-string suture. This technique not only aids in excision and minimizes blood loss, but also preserves fertility [14].

Conclusions

Early diagnosis and treatment are of significant importance in managing cornual pregnancies as cornual pregnancies are at risk of rupture. This rupture presents later and with more severe bleeding compared to those of other ectopic pregnancies, leading to catastrophic hemorrhage. Management of cornual pregnancies is centered on limiting hemorrhage. The tourniquet purse-string suture technique aids in removal of this pregnancy, as well as minimizes blood loss and preserves the patient's fertility.

Additional Information

Disclosures

Human subjects: Consent was obtained or waived by all participants in this study. **Conflicts of interest:** In compliance with the ICMJE uniform disclosure form, all authors declare the following: **Payment/services info:** All authors have declared that no financial support was received from any organization for the submitted work. **Financial relationships:** All authors have declared that they have no financial relationships at present or within the previous three years with any organizations that might have an interest in the submitted work. **Other relationships:** All authors have declared that there are no other relationships or activities that could appear to have influenced the submitted work.

References

1. Tulandi T, Al-Jaroudi D: Interstitial pregnancy: results generated from the Society of Reproductive Surgeons Registry. *Obstet Gynecol.* 2004, 105:47-50. [10.1097/01.AOG.0000109218.24211.79](https://doi.org/10.1097/01.AOG.0000109218.24211.79)
2. Abdelazim IA, Shikanova S, Bekzhanova M: Regarding "Laparoscopic Management 4 Cases of Recurrent Cornual Ectopic Pregnancy and Review of Literature". *J Minim Invasive Gynecol.* 2019, 26:774. [10.1016/j.jmig.2018.11.020](https://doi.org/10.1016/j.jmig.2018.11.020)
3. Moawad NS, Mahajan ST, Moniz MH, Taylor SE, Hurd WW: Current diagnosis and treatment of interstitial pregnancy. *Am J Obstet Gynecol.* 2010, 202:15-29. [10.1016/j.ajog.2009.07.054](https://doi.org/10.1016/j.ajog.2009.07.054)
4. Walid MS, Heaton RL: Diagnosis and laparoscopic treatment of cornual ectopic pregnancy. *Ger Med Sci.* 2010, 8:Doc16. [10.5205/000105](https://doi.org/10.5205/000105)
5. Rock J, Jones H: *Te Linde's Operative Gynecology*. Wolters Kluwer Health/Lippincott Williams & Wilkins, Philadelphia, PA; 2008. <https://www.moscomm.org/pdf/Telindes%20gynecology.pdf>.
6. Chopra S, Keepanasseril A, Rohilla M, Bagga R, Kalra J, Jain V: Obstetric morbidity and the diagnostic dilemma in pregnancy in rudimentary horn: retrospective analysis. *Arch Gynecol Obstet.* 2009, 280:907-910. [10.1007/s00404-009-1013-4](https://doi.org/10.1007/s00404-009-1013-4)
7. Tenore JL: Ectopic pregnancy. *Am Fam Physician.* 2000, 61:1080-1088.
8. Lau S, Tulandi T: Conservative medical and surgical management of interstitial ectopic pregnancy. *Fertil Steril.* 1999, 72:207-215. [10.1016/S0015-0282\(99\)00242-3](https://doi.org/10.1016/S0015-0282(99)00242-3)
9. Moon HS, Choi YJ, Park YH, Kim SG: New simple endoscopic operations for interstitial pregnancies. *Am J Obstet Gynecol.* 2000, 182:114-121. [10.1016/S0002-9378\(00\)70499-6](https://doi.org/10.1016/S0002-9378(00)70499-6)
10. Timor-Tritch IE, Monteagudo A, Matera C, Veit CR: Sonographic evolution of cornual pregnancies treated without surgery. *Obstet Gynecol.* 1992, 79:1044-1049.
11. Tang A, Baartz D, Khoo SK: A medical management of interstitial ectopic pregnancy: a 5-year clinical study. *Aust N Z J Obstet Gynaecol.* 2006, 46:107-111. [10.1111/j.1479-828X.2006.00537.x](https://doi.org/10.1111/j.1479-828X.2006.00537.x)
12. Tawfiq A, Agameya AF, Claman P: Predictors of treatment failure for ectopic pregnancy treated with single-dose methotrexate. *Fertil Steril.* 2000, 74:877-880. [10.1016/s0015-0282\(00\)01547-8](https://doi.org/10.1016/s0015-0282(00)01547-8)
13. Potter MB, Lepine LA, Jamieson DJ: Predictors of success with methotrexate treatment of tubal ectopic pregnancy at Grady Memorial Hospital. *Am J Obstet Gynecol.* 2003, 188:1192-1194. [10.1067/mob.2003.310](https://doi.org/10.1067/mob.2003.310)
14. Afifi Y, Mahmud A, Fatma A: Hemostatic techniques for laparoscopic management of cornual pregnancy: double-impact devascularization technique. *J Minim Invasive Gynecol.* 2016, 23:274-280. [10.1016/j.jmig.2015.09.002](https://doi.org/10.1016/j.jmig.2015.09.002)