

Baptist Health South Florida

Scholarly Commons @ Baptist Health South Florida

All Publications

2020

Cardiac Myxoma with Cerebral Metastases and Chronic Lymphocytic Leukemia/Small Lymphocytic Lymphoma: A Case Report and Review

Manuel Menes

Baptist Health South Florida, menesm@bellsouth.net

Vitaly Siomin

Baptist Health Medical Group; Miami Cancer Institute; Miami Neuroscience Institute,
vitalys@baptisthealth.net


Follow this and additional works at: <https://scholarlycommons.baptisthealth.net/se-all-publications>

Citation

J Neurol Surg Rep (2020) 81(1):e1-e6

This Article -- Open Access is brought to you for free and open access by Scholarly Commons @ Baptist Health South Florida. It has been accepted for inclusion in All Publications by an authorized administrator of Scholarly Commons @ Baptist Health South Florida. For more information, please contact Carrief@baptisthealth.net.

Cardiac Myxoma with Cerebral Metastases and Chronic Lymphocytic Leukemia/Small Lymphocytic Lymphoma: A Case Report and Review

Jared A. Maas¹  Manuel Menes² Vitaly Siomin³

¹ Department of Radiation Oncology, University of Alabama at Birmingham, Hazelrig Salter Radiation Oncology Center, Birmingham, Alabama, United States

² Department of Pathology, Baptist Health South Florida, Miami, Florida, United States

³ Department of Neurosurgery, Baptist Health South Florida, Miami, Florida, United States

Address for correspondence Jared A. Maas, MD, Department of Radiation Oncology, University of Alabama at Birmingham, Hazelrig Salter Radiation Oncology Center, 1719 6th Avenue South, Birmingham, AL 35294, United States (e-mail: jaredamaas@gmail.com).

J Neurol Surg Rep 2020;81:e1–e6.

Abstract

Background Cardiac myxomas, the most common primary cardiac tumors, are generally benign neoplasms. Primary cardiac lymphoma is a rare cardiac malignancy with a very poor prognosis. Here we present a case of a cardiac myxoma with cerebral metastases and chronic lymphocytic leukemia/small lymphocytic lymphoma (CLL/SLL) arising within the cerebral metastases.

Case description A 62-year-old man, who presented with symptoms of multiple transient ischemic attacks, was found to have a left atrial myxoma. Twelve months after excision of the myxoma, the patient experienced a recurrence of neurologic symptoms. Brain magnetic resonance imaging revealed multiple hemorrhagic masses. Craniotomy was performed to resect the lesions. Histopathologic examination confirmed cardiac myxoma metastases and a small lymphocytic infiltrate within the tumor consistent with CLL/SLL.

Conclusion Including the present case, there are 27 cases of cardiac myxoma cerebral metastases and 22 cases of lymphomas arising within myxomas. The present case is the first known instance of both entities in the same patient. There is no standard management for either cardiac myxoma metastases or lymphoma within a myxoma. For both diseases, surgical excision is the primary treatment modality, but postoperative chemotherapy and/or radiation have been attempted. Myxomas may create a chronic inflammatory state that could lead to the development of CLL/SLL.

Keywords

- ▶ cardiac myxoma
- ▶ atrial myxoma
- ▶ cerebral metastases
- ▶ lymphoma
- ▶ CLL/SLL

Introduction

Primary cardiac tumors are rare, occurring in 0.02 to 2.8% of autopsy series; a plurality of these cases are cardiac myxomas, which account for 30 to 50% of primary cardiac tumors in pathologic series.¹ The vast majority of cardiac myxomas—~83% of cases—occur in the left atrium, while 13% occur in

the right atrium.¹ Demographically, patients are diagnosed at a mean age of 50 with nearly a 2:1 female predominance.¹ Myxomas are generally benign tumors¹ that are thought to be derived from endocardial multipotent mesenchymal cells.^{2,3} However, they have a higher risk of recurrence in the setting of incomplete resection, multiple foci, and tumor embolism.²

received
July 28, 2019
accepted
September 28, 2019

DOI <https://doi.org/10.1055/s-0039-3399570>.
ISSN 2193-6358.

© 2020 Georg Thieme Verlag KG
Stuttgart · New York

License terms



While the most common clinical presentation of cardiac myxomas is dyspnea secondary to congestive heart failure,⁴ as many as 50% of the reported cases of atrial myxomas present with complications due to embolization, and up to half of these cases present with neurologic manifestations.⁵ Among these neurologic manifestations, atrial myxomas can cause infarction, aneurysm, or rarely metastasis.⁵ To date, only 27 cases of cardiac myxoma metastasis to the brain have been reported, including the present case.

Primary cardiac lymphoma is also particularly rare, amounting to less than 2% of all primary cardiac tumors.³ The most common histological subtype of primary cardiac lymphoma is large B cell lymphoma.⁶ Most cases of primary cardiac lymphoma occur in immunocompromised patients.⁶ The outlook for these patients is generally poor—the median survival is 7 months after initial diagnosis.⁶ Primary cardiac lymphoma arising within cardiac myxoma is exceedingly rare with only 22 reported cases since 2009, including the present case.^{3,7}

The present case is the first known case of myxoma metastases and lymphoma arising within myxoma occurring in the same patient. Additionally, it is the first known instance of a lymphoma arising within cardiac myxoma metastases rather than within the cardiac primary tumor.

Case Report

A 62-year-old male patient with a past medical history of hypertension, hypertrophic cardiomyopathy, and an episode of left arm numbness in April 2016 initially presented to the hospital with mild chest discomfort, left arm numbness, visual changes, and gait instability in June 2016. The patient underwent stroke workup including a magnetic resonance imaging (MRI) of the brain, which demonstrated hemorrhagic lesions to the brain and transesophageal echocardiography, which revealed a 4.2 × 2.4 cm (centimeters) mass in the left atrium. Gross total resection of the cardiac lesion was performed under cardiopulmonary bypass through a right thoracotomy approach in July of 2016. The patient had an uneventful postoperative course. Echocardiography showed no evidence of residual tumor. Histopathologic examination confirmed a diagnosis of left atrial myxoma. In December 2016, the patient presented to the hospital with painful fingertip nodules. Following resection of these lesions, histopathologic evaluation proved that these lesions were myxomatous.

The patient returned to the hospital in June 2017, 12 months after his initial presentation, complaining of 2 weeks of weakness and clumsiness of the left upper extremity and episodes of blurred vision lasting 30 to 40 minutes several times a week. Repeat transesophageal echocardiogram showed no evidence of intracardiac recurrence. Brain MRI performed with and without contrast demonstrated enlarged heterogeneously enhancing hemorrhagic masses in the right posterior occipital–parietal region with increased vasogenic edema and mild mass-effect on the posterior horn of the right lateral ventricle (►Fig. 1). The dominant enlarging hemorrhagic lesion measured 36 × 36 × 37 mm (millimeter) and a second measured 18 × 14 × 12 mm. Three other lesions from previous scans in the

posterior frontal and parieto-occipital regions were decreasing or resolved. Image-guided right parieto-occipital craniotomy with neuromonitoring for resection of the dominant and three other lesions was performed. Four tan hemorrhagic soft tissue specimens were submitted for histopathologic evaluation, which demonstrated metastatic atrial myxoma and a small lymphocytic lymphoma/chronic lymphocytic leukemia arising (SLL/CLL) from within the metastatic atrial myxoma (►Fig. 1). The atypical predominantly perivascular small lymphocytic infiltrate within the tumor revealed a PAX (paired box gene)-5+/CD (cluster of differentiation)20-/CD5+/CD3-/CD23+ (partial)/BCL (B cell lymphoma)-6-/cyclin D1- immunophenotype on immunoperoxidase stains (►Fig. 1). These immunohistochemical results, together with the morphologic features, are consistent with CLL/SLL. There was no evidence of lymphoma outside the myxoma. Neither chemotherapy nor radiotherapy was administered.

Following the procedure, the patient recovered well. Postoperative MRI showed postoperative changes and no evidence of residual tumor. The patient was placed on levetiracetam prophylactically for 5 days. He initially reported worsening visual fields on postoperative day 1, which partially resolved by postoperative day 2. There were no other signs or symptoms. The patient was discharged on postoperative day 2 for close outpatient follow-up. As of a 48-month follow-up visit, the patient was doing well with continuous visual field improvement and no evidence of disease.

Discussion

There are 27 cases—including the present case—of a cardiac myxoma metastasizing to the brain reported in the literature (►Table 1).² The authors are aware of only one other case of histopathologically proven CLL/SLL within a cardiac myxoma⁸ and only 21 other cases of lymphomas within a cardiac myxoma (►Table 2).^{3,7} The present case also represents the first known instance of a lymphoma arising within a myxomatous cerebral metastasis.

As this is the first reported case of both cardiac myxoma metastases and lymphoma within a cardiac myxoma in the same patient, it is unclear if the presence of lymphoma is related to the metastatic potential of an otherwise usually benign tumor. Cardiac myxomas are thought to metastasize secondary to embolism prior to or during surgical handling.² Despite this, embolic manifestations can be delayed months or even years.^{2,13,14} This patient's additional presentation with myxomatous involvement of the extremities 6 months after his initial presentation supports the theory of arterial embolization. Additionally, cardiac myxomas are known to secrete several inflammatory cytokines such as endothelin-1, interleukin-6, cysteine X cysteine cytokines, interleukin-8, and growth-related oncogene α .⁴⁶ It is also known that chronic inflammation in several inflammatory conditions is associated with the development of lymphoma.⁴⁷ Therefore, a more parsimonious hypothesis is that the CLL/SLL arose within the cardiac myxoma metastases because of the chronic inflammatory state created by the

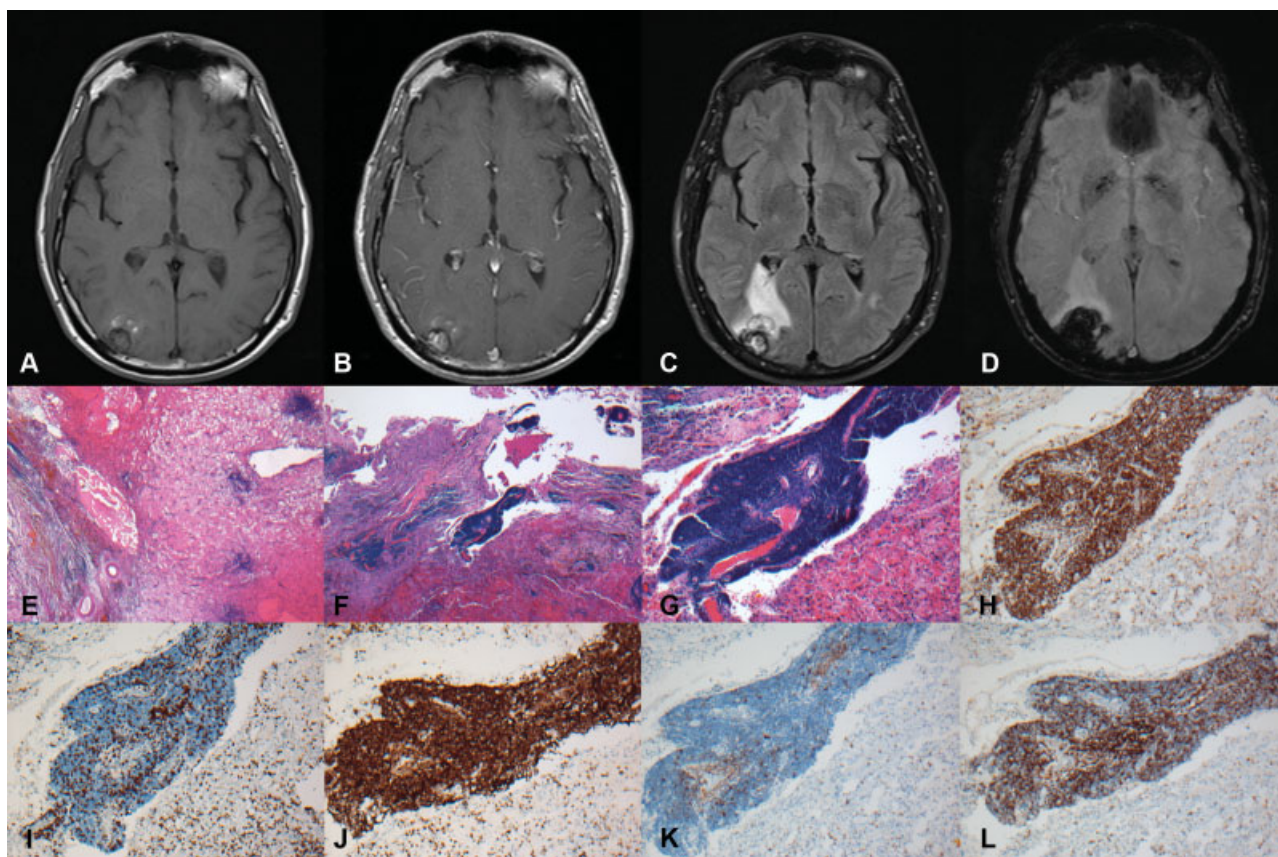


Fig. 1 A magnetic resonance imaging T1-weighted image prior to gadolinium administration, demonstrated a lesion in the parieto-occipital region (A). The T1-weighted image after gadolinium injection showed enhancement in the center of the mass (B). Fluid attenuation inversion recovery image showed perifocal edematous changes extending to the atrium and occipital horn of the right lateral ventricle (C). Gradient echo image amplified the artifact caused by hemorrhagic products in and around the mass (D). Microscopic examination at 2x magnification reveals metastatic myxoma with dense lymphoid infiltrates (E and F). Further examination at 10x magnification shows the lymphoid infiltrate within myxoma is tightly cuffing blood vessels (G). Immunohistochemistry at 10x magnification reveals Pax 5 stain positive in infiltrate indicating B cell lineage (H), CD3 stain demonstrates only few T cells (I), CD5 stain expression in the B cell infiltrate (J), negative cyclin D1 stain excludes mantle cell lymphoma (K), and CD23 stain is positive in the small B cell infiltrate (L).

myxoma.^{3,39,41,43} Given the present case's neurologic manifestations prior to diagnosis of his cardiac myxoma, it is possible that the cerebral metastases were present several months before they were formerly diagnosed; if so, this longstanding inflammation would potentially allow for malignant transformation. Laird-Fick et al⁸ hypothesize that a shared genetic defect could be the link between myxoma and CLL/SLL, noting that abnormalities on chromosomes 12 and 17 as well as in the protein kinase-A pathway (including Carney complex gene mutations) have been associated with both tumors. A recent study showed that myxomas express elevated oncogenes and malignancy-related proteins such as c-MYC, p53, vimentin, and hypoxia-inducible factor 1- α compared with normal heart tissue. This suggests that even though myxomas often clinically behave as benign tumors, they possess latent oncogenic and metastatic potential.⁴⁸

It is also notable that lymphomas arising within cardiac myxomas do not behave like primary cardiac lymphomas. While most cases of primary cardiac lymphoma occur in immunocompromised patients, all 22 reported cases of lymphoma within myxoma occurred in immunocompetent

patients (**Table 2**).⁶ The prognosis for lymphoma arising within myxoma also seems to be better than the 7-month median survival associated with primary cardiac lymphoma (**Table 2**).⁶ However, the sample size and follow-up data are limited so caution should be used when interpreting these data.

Because cardiac myxomas with cerebral metastases are extremely rare, there is no established gold standard treatment (**Table 1**). Surgical excision seems to be the primary approach for diagnostic purposes, treatment of one to two isolated brain metastases, or treatment when one of several lesions is life-threatening.^{10,14} Radiation therapy can be used as a possible alternative treatment in patients with multiple metastases or as a supplementary treatment for patients who do not experience resolution with surgery alone.^{2,12-14,18} Most often, radiotherapy consisted of palliative whole brain radiation at 25 to 30 Gy (Gray),^{2,13,14} but doses as high as 40.8¹² and 50 Gy¹⁸ have been attempted with positive results. Postoperative chemoradiotherapy using ifosfamide and doxorubicin and postoperative chemotherapy using doxorubicin alone have been attempted in two cases with positive and equivocal results, respectively.^{2,18}

Table 1 Reported cases of histopathologically proven cardiac myxoma metastasizing to the brain^a

Case	Report (reference)	Year	Age	Interval to recurrence (months)	Other recurrent sites	Surgery for brain lesions	RT	CT	Outcome follow-up (months)
1	Maas [our case]	2019	62	12	Fingertips	Yes	No	No	NED48
2	Rose et al case 1 ²	2016	44	5	No	No	Yes	No	DOD17
3	Rose et al case 2 ²	2016	52	0	No	No	No	Yes	AWD63
4	Badriyah et al ⁹	2012	15	36	No	Yes	No	No	NED72
5	Radoi et al ¹⁰	2012	45	18	No	Yes	No	No	AWD12
6	Kumar et al ¹¹	2011	30	24	No	Yes	No	No	?
7	Suzuki et al ¹²	2008	68	6	No	Yes	Yes	No	?
8	Moiyadi et al ¹³	2007	35	48	No	Yes	Yes	No	AWD6
9	Altundag et al ¹⁴	2005	41	15	No	Yes	Yes	No	AWD63
10	Acikel et al ¹⁵	2004	58	0	No	No	No	No	?
11	Hirundayaraj et al ¹⁶	2004	50	-1	No	Yes	No	No	?
12	Hou et al ¹⁷	2001	37	10	Bone	No	No	No	DOD12
13	Bernet et al ¹⁸	1998	31	2	Muscle, lung	Yes	Yes	Yes	NED120
14	Scarpelli et al ¹⁹	1997	64	144	No	Yes	No	No	?
15	Samaratunga et al ²⁰	1994	60	-7	No	Yes	No	No	NED21
16	Kanda et al ²¹	1994	70	-7	No	Yes	No	No	NED9
17	Chozick et al ²²	1992	61	8	No	Yes	No	No	NED72
18	Todo et al ²³	1992	32	10	Jejunum	No	No	No	DOD10
19	Kotani et al ²⁴	1991	48	3	Soft tissue, aorta	Yes	No	No	DOD53
20	Ng et al ²⁵	1990	54	6	No	Yes	No	No	AWD18
21	de Morais et al ²⁶	1988	73	0	Kidney, pancreas, stomach	No	No	No	DOD1
22	Bazin et al ²⁷	1987	56	48	No	Yes	No	No	?
23	Kadota et al ²⁸	1987	44	3	Skin	Yes	No	No	?
24	Markel et al ²⁹	1986	18	30	Bone	No	No	No	AWD39
25	Seo et al ³⁰	1980	36	96	Bone	Yes	No	No	AWD120
26	Budzilovich et al ³¹	1979	52	0	No	No	No	No	DOD1
27	Rankin and DeSousa ³²	1978	44	96	No	Yes	No	No	AWD120

Abbreviations: AWD, alive with disease; CT, chemotherapy; DOD, died of disease; NED, no evidence of disease; RT, radiotherapy.

^aAdapted from Rose et al 2016,² Moiyadi et al 2007,¹³ and Altdung et al 2005¹⁴; added Kumar et al¹¹ and Suzuki et al.¹²

Note: “?” refers to unknown outcome.

Additionally, the standard management of lymphomas arising within cardiac myxomas has not yet been determined because the cases occur so infrequently (→ **Table 2**). While 7 out of the 22 cases have been treated with postoperative chemotherapy, it is not clear if chemotherapy is needed in the setting of disease confined within the myxoma status post total resection.³ One out of the 22 cases died as a result of chemotherapy-induced neutropenic fever and opportunistic pneumonia⁴² and three other cases that did not receive postoperative chemotherapy had no evidence of disease recurrence at a six-,⁴⁰ ten-,⁷ and eleven-³⁶ year follow-up. Furthermore, it is possible that the lymphoma remains localized completely within the myxoma, and if so, it may

be prudent to withhold postsurgical chemotherapy until the patient develops a recurrence.^{3,7,39–41,43} As of now, the patient presented in this report has been treated with surgery alone.

Further characterization of cardiac myxomas through molecular markers might allow for a better understanding of the pathogenesis of cardiac myxoma and myxomatous metastases as well as more rapid diagnosis of this rare disease. Future studies examining the potential for a related pathogenesis between cardiac myxoma and CLL/SLL might also improve the generalizable knowledge surrounding these two diseases. Additional case reports and follow-up may elucidate the most appropriate treatments for cardiac

Table 2 Reported cases of histopathologically proven lymphoma within cardiac myxoma^a

Case	Report (Reference)	Year	Age	Sex	Location	Phenotype	Immune status	Chemotherapy	Outcome follow-up (months)
1	Maas (our case)	2019	62	M	Intracranial met from left atrium	CLL	IP	None	NED48
2	Garces and Sriganeshan ³³	2019	50	M	Left atrium	FA-DLBCL	IP	None	NED65
3	Park et al ³⁴	2018	44	M	Left atrium, Right CFA embolus	nGC-DLBCL	IP	R-CHOP x 6	None
4	Yan et al case 1 ⁷	2017	46	F	Left atrium	nGC-DLBCL	IP	None	NED120
5	Yan et al case 2 ⁷	2017	61	F	Left atrium	GC-DLBCL	IP	None	NED84
6	Yan et al case 3 ⁷	2017	54	M	Left atrium	nGC-DLBCL	IP	None	NED7
7	Yan et al case 4 ⁷	2017	46	F	Left atrium	nGC-DLBCL	IP	None	NED3
8	Jiang et al ³⁵	2017	63	M	Left atrium	nGC-DLBCL	IP	None	NED7
9	Boyer et al case 1 ³⁶	2017	54	F	Left atrium	nGC-DLBCL	IP	NA	NED130
10	Boyer et al case 2 ³⁶	2017	55	F	Left atrium	nGC-DLBCL	IP	None	DOC2 ^b
11	Boyer et al case 3 ³⁶	2017	54	M	Left atrium	nGC-DLBCL	IP	None	DOD26 ^c
12	Pineda et al ³⁷	2015	50	M	Left atrium	HGBCL	IP	NA	None
13	Aguilar et al ³⁸	2015	52	M	Left atrium	nGC-DLBCL	IP	None	NED42
14	Liu et al ³	2015	52	M	Left atrium	nGC-DLBCL	IP	None	NED3
15	Tapan et al ³⁹	2015	49	M	Left atrium	nGC-DLBCL	IP	CHOP × 6	NED12
16	Laird-Fick et al ⁸	2014	56	F	Left atrium	CLL	IP	FCR × NA	AWD18 ^d
17	Bartoloni et al ⁴⁰	2013	55	F	Left atrium	ALBP	IP	None	NED72
18	Svec et al ⁴¹	2012	60	F	Left atrium	nGC-DLBCL	IP	CHOP × 6	NED7
19	Loong et al ⁴²	2010	70	F	Left atrium	nGC-DLBCL	IP	CEOP × 4	DOC5 ^e
20	Dimitrova et al ⁴³	2010	51	M	Left atrium	GC-DLBCL	IP	CHOP × 6	None
21	White et al ⁴⁴	2010	75	F	Left atrium	PLL	IP	NA	None
22	Bagwan et al ⁴⁵	2009	81	F	Left atrium	GC-DLBCL	IP	R-CHOP × NA	None

Abbreviations: ALBP, atypical lymphoid B-cell proliferation; AWD, alive with disease; CFA, common femoral artery; CLL, chronic lymphocytic leukemia; DOC, died of other cause; DOD, died of disease; FA-DLBCL, fibrin associated diffuse large B-cell lymphoma; FCR, fludarabine, cyclophosphamide, and rituximab; HGBCL, high grade B-cell lymphoma; IP, immunocompetent patient; NA, not available. R-CHOP, rituximab cyclophosphamide, doxorubicin, vincristine, and prednisone; NED, no evidence of lymphoma recurrence or dissemination; nGC-DLBCL, nongerminal center diffuse large B-cell lymphoma; PL, plasmacytic lymphoma; R-CEOP, rituximab, cyclophosphamide, epirubicin, vincristine, and prednisone.

^aAdapted from Yan et al 2017⁷ and Liu et al 2015³; added Maas et al (our case), Jiang et al,³⁵ Pineda et al,³⁷ Garces et al,³³ and Park et al.³⁴

^bCardiomegaly, myocardial infarction.

^cEmbolic strokes.

^dLocal recurrence at 18 months after no chemotherapy; began FCR chemotherapy, with clinical remission.

^eComplications of chemotherapy.

myxoma metastases and lymphoma with cardiac myxoma leading to better patient outcomes.

Conflicts of Interest

The authors declare that there are no conflicts of interest. This research did not receive any specific grant from funding agencies in the public, commercial, or not-for-profit sectors.

References

- 1 Kuon E, Kreplin M, Weiss W, Dahm JB. The challenge presented by right atrial myxoma. *Herz* 2004;29(07):702–709
- 2 Rose D, Papa A, Tomao S, Greco E, Zacharias J. Cerebral metastases in patients with left atrial myxoma. *J Card Surg* 2016;31(05):289–293
- 3 Liu X, Liu P, Li J. EBV+ diffuse large B-cell lymphoma arising within atrial myxoma in Chinese immunocompetent patient. *Int J Clin Exp Pathol* 2015;8(02):2159–2164
- 4 Shimono T, Makino S, Kanamori Y, Kinoshita T, Yada I. Left atrial myxomas. Using gross anatomic tumor types to determine clinical features and coronary angiographic findings. *Chest* 1995;107(03):674–679
- 5 Desousa AL, Muller J, Campbell R, Batnitzky S, Rankin L. Atrial myxoma: a review of the neurological complications, metastases, and recurrences. *J Neurol Neurosurg Psychiatry* 1978;41(12):1119–1124

- 6 Miguel CE, Bestetti RB. Primary cardiac lymphoma. *Int J Cardiol* 2011;149(03):358–363
- 7 Yan J, Luo D, Zhang F, et al. Diffuse large B cell lymphoma associated with chronic inflammation arising within atrial myxoma: aggressive histological features but indolent clinical behaviour. *Histopathology* 2017;71(06):951–959
- 8 Laird-Fick H, Tiwari A, Narayanan S, Qin Y, Vodnala D, Bhutani M. A case of comorbid myxoma and chronic lymphocytic leukemia: not just a coincidence? *Case Rep Oncol Med* 2014;2014:142746
- 9 Badriyah I, Saiful R, Rahmat H, Naik VR, Tan YC. Brain metastasis of atrial myxoma: case report. *Med J Malaysia* 2012;67(06):613–615
- 10 Radoi MP, Stefanescu F, Arsene D. Brain metastases and multiple cerebral aneurysms from cardiac myxoma: case report and review of the literature. *Br J Neurosurg* 2012;26(06):893–895
- 11 Kumar A, Deopujari CE, Karmarkar VS. A rare diagnosis of multiple hemorrhagic metastases in brain. *J Postgrad Med* 2011;57(03):214–217
- 12 Suzuki R, Watanabe T, Hirayama R, et al. [Case with cardiac myxoma causing cerebral metastasis after cardiac tumor resection]. *Kyobu Geka* 2008;61(06):456–459
- 13 Moiyadi AV, Moiyadi AA, Sampath S, et al. Intracranial metastasis from a glandular variant of atrial myxoma. *Acta Neurochir (Wien)* 2007;149(11):1157–1162
- 14 Altundag MB, Ertas G, Ucer AR, et al. Brain metastasis of cardiac myxoma: case report and review of the literature. *J Neurooncol* 2005;75(02):181–184
- 15 Acikel M, Yekeler I, Ates A, Erkut B. A giant left atrial myxoma: an unusual cause of syncope and cerebral emboli. *Int J Cardiol* 2004;94(2-3):325–326
- 16 Hirudayaraj P, Arya B, Suvarna SK, Payne G, Palaniswamy A. Myxomatous meningeal tumour: a case of “metastatic” cardiac myxoma. *Int J Cardiol* 2004;96(03):471–473
- 17 Hou YC, Chang S, Lo HM, Hsiao CH, Lin FY. Recurrent cardiac myxoma with multiple distant metastasis and malignant change. *J Formos Med Assoc* 2001;100(01):63–65
- 18 Bernet F, Stulz PM, Carrel TP. Long-term remission after resection, chemotherapy, and irradiation of a metastatic myxoma. *Ann Thorac Surg* 1998;66(05):1791–1792
- 19 Scarpelli M, Montironi R, Ricciuti R, Vecchioni S, Pauri F. Cardiac myxoma with glandular elements metastatic to the brain 12 years after the removal of the original tumor. *Clin Neuropathol* 1997;16(04):190–194
- 20 Samaratunga H, Searle J, Cominos D, Le Fevre I. Cerebral metastasis of an atrial myxoma mimicking an epithelioid hemangioendothelioma. *Am J Surg Pathol* 1994;18(01):107–111
- 21 Kanda T, Sakamaki T, Murata K. A cardiac myxoma with interleukin-6 production and cerebral metastasis. *Int J Cardiol* 1994;45(02):144–146
- 22 Chozick BS, Ambler MW, Stoll J Jr. Malignant astrocytoma six years after the resection of a cerebral metastatic cardiac myxoma: case report. *Neurosurgery* 1992;30(06):923–926, discussion 926–927
- 23 Todo T, Usui M, Nagashima K. Cerebral metastasis of malignant cardiac myxoma. *Surg Neurol* 1992;37(05):374–379
- 24 Kotani K, Matsuzawa Y, Funahashi T, et al. Left atrial myxoma metastasizing to the aorta, with intraluminal growth causing renovascular hypertension. *Cardiology* 1991;78(01):72–77
- 25 Ng HK, Poon WS. Cardiac myxoma metastasizing to the brain. Case report. *J Neurosurg* 1990;72(02):295–298
- 26 de Moraes C, Falzoni R, Alves VA. Myocardial infarct due to a unique atrial myxoma with epithelial-like cells and systemic metastases. *Arch Pathol Lab Med* 1988;112(02):185–190
- 27 Bazin A, Peruzzi P, Baudrillard JC, Pluot M, Rousseaux P. [Cardiac myxoma with cerebral metastases]. *Neurochirurgie* 1987;33(06):487–489
- 28 Kadota T, Imakita S, Mitomo M, et al. Metastatic brain tumor of atrial myxoma. *Neuroradiology* 1987;29(02):218
- 29 Markel ML, Armstrong WF, Waller BF, Mahomed Y. Left atrial myxoma with multicentric recurrence and evidence of metastases. *Am Heart J* 1986;111(02):409–413
- 30 Seo IS, Warner TF, Colyer RA, Winkler RF. Metastasizing atrial myxoma. *Am J Surg Pathol* 1980;4(04):391–399
- 31 Budzilovich G, Aleksic S, Greco A, Fernandez J, Harris J, Finegold M. Malignant cardiac myxoma with cerebral metastases. *Surg Neurol* 1979;11(06):461–469
- 32 Rankin LI, DeSousa AL. Metastatic atrial myxoma presenting as intracranial mass. *Chest* 1978;74(04):451–452
- 33 Garces S, Sriganeshan V. Fibrin-associated diffuse large B-cell lymphoma confined to a cardiac myxoma. *Blood* 2019;133(08):882
- 34 Park CK, Cho YA, Kim M, Shim HS. Malignant lymphoma arising in cardiac myxoma, presenting with peripheral arterial emboli. *Cardiovasc Pathol* 2018;32:26–29
- 35 Jiang YY, Jiang CW, Wang LP. [Epstein-Barr virus-positive large B-cell lymphoma arising within atrial myxoma: report of a case]. *Zhonghua Bing Li Xue Za Zhi* 2017;46(04):273–274
- 36 Boyer DF, McKelvie PA, de Leval L, et al. Fibrin-associated EBV-positive large B-cell lymphoma: an indolent neoplasm with features distinct from diffuse large B-cell lymphoma associated with chronic inflammation. *Am J Surg Pathol* 2017;41(03):299–312
- 37 Pineda AM, Mihos CG, Nascimento FO, Santana O, Lamelas J, Beohar N. Coronary embolization from a left atrial myxoma containing malignant lymphoma cells. *Tex Heart Inst J* 2015;42(06):565–568
- 38 Aguilar C, Beltran B, Quiñones P, et al. Large B-cell lymphoma arising in cardiac myxoma or intracardiac fibrinous mass: a localized lymphoma usually associated with Epstein-Barr virus? *Cardiovasc Pathol* 2015;24(01):60–64
- 39 Tapan U, Pestana JB, Lee JC, Lerner A. Epstein-Barr virus-associated diffuse large B-cell lymphoma arising in atrial myxoma: a proposal for a modified therapeutic approach. *Leuk Lymphoma* 2015;56(02):505–507
- 40 Bartoloni G, Pucci A, Giorlandino A, et al. Incidental Epstein-Barr virus associated atypical lymphoid proliferation arising in a left atrial myxoma: a case of long survival without any postsurgical treatment and review of the literature. *Cardiovasc Pathol* 2013;22(03):e5–e10
- 41 Svec A, Rangaiah M, Giles M, Jaks R, McAulay KA. EBV+ diffuse large B-cell lymphoma arising within atrial myxoma. An example of a distinct primary cardiac EBV+ DLBCL of immunocompetent patients. *Pathol Res Pract* 2012;208(03):172–176
- 42 Loong F, Chan AC, Ho BC, et al. Diffuse large B-cell lymphoma associated with chronic inflammation as an incidental finding and new clinical scenarios. *Mod Pathol* 2010;23(04):493–501
- 43 Dimitrova KR, Hoffman DM, Geller CM, et al. Malignant B-cell lymphoma arising in a large, left atrial myxoma. *Ann Thorac Surg* 2010;89(02):626–629
- 44 White RW, Hirst NA, Edward S, Nair UR. Plasmacytoid lymphoma within a left atrial myxoma: a rare coincidental dual pathology. *Interact Cardiovasc Thorac Surg* 2010;10(01):140–141
- 45 Bagwan IN, Desai S, Wotherspoon A, Sheppard MN. Unusual presentation of primary cardiac lymphoma. *Interact Cardiovasc Thorac Surg* 2009;9(01):127–129
- 46 Sakamoto H, Sakamaki T, Sumino H, et al. Production of endothelin-1 and big endothelin-1 by human cardiac myxoma cells—implications of the origin of myxomas—. *Circ J* 2004;68(12):1230–1232
- 47 Smedby KE, Baecklund E, Askling J. Malignant lymphomas in autoimmunity and inflammation: a review of risks, risk factors, and lymphoma characteristics. *Cancer Epidemiol Biomarkers Prev* 2006;15(11):2069–2077
- 48 Pacheco-Velázquez SC, Gallardo-Pérez JC, Díaz D, et al. Heart myxoma develops oncogenic and metastatic phenotype. *J Cancer Res Clin Oncol* 2019;145(05):1283–1295