Baptist Health South Florida

Scholarly Commons @ Baptist Health South Florida

All Publications

2016

Gangliocytomas and Gangliogliomas: Review of Clinical, Pathologic and Genetic Features

Yazmin Odia
Miami Cancer Institute, yazmino@baptisthealth.net

Follow this and additional works at: https://scholarlycommons.baptisthealth.net/se-all-publications

Citation
Clinics in Oncology (2016) 1:1017

This Article -- Open Access is brought to you for free and open access by Scholarly Commons @ Baptist Health South Florida. It has been accepted for inclusion in All Publications by an authorized administrator of Scholarly Commons @ Baptist Health South Florida. For more information, please contact Carrief@baptisthealth.net.

Clinics in Oncology

Review Article
Published: 14 Jun, 2016

Gangliocytomas and Gangliogliomas: Review of Clinical, Pathologic and Genetic Features

*Yazmin Odia**

Neuro-Oncology, Miami Cancer Institute, Baptist Health South Florida, USA

Abstract

Gangliocytomas and Gangliogliomas are well-differentiated, slowly growing neuroepithelial tumors, composed of neoplastic, mature ganglion cells alone or in combination with neoplastic glial cells, respectively. Surgical resection is the standard of care, radiation used for malignant features or unresectable tumors. The epidemiology, clinical, pathologic and genetic features of these rare primary brain tumors are described.

Keywords: Gangliocytomas; Gangliogliomas; Review; Chromosomal imbalances; CDKN2A

Introduction

Historical perspective

Gangliocytomas and gangliogliomas are well-differentiated, slowly growing neuroepithelial tumors, composed of neoplastic, mature ganglion cells alone or in combination with neoplastic glial cells, respectively [1]. "Gangliogliomas" were first described by James Ewing in 1926 and adopted by Cyril B. Courville in 1930 [2]. According to the 2007 World Health Organization (WHO) classification, both gangliogliomas and gangliocytomas are benign tumors (WHO grade I), [1] but malignant transformations to anaplastic ganglioglioma, WHO grade III, have been reported [3]. In large series, WHO grade I, II and III tumors comprise 86%, 9% and 5% of all gangliogliomas, while <1% show features consistent with glioblastoma (WHO grade IV) [4,5].

The benign (WHO grade I) dysplastic gangliocytoma of the cerebellum (also called Lhermitte-Dulcos) was first described by J. Lhermitte and P. Duclos and Spiegel in 1920, [6] but only recently recognized as part of Cowden syndrome. Cowden syndrome or multiple hamartoma-neoplasia syndrome, is an uncommon autosomal dominant disorder characterized by mucocutaneous lesions and systemic malignanciesc [1,7].

Epidemiology

Ganglioglioma and gangliocytomas together comprise 0.4% of all CNS and 1.3% of all brain tumors based on larger surgical series [1,8,9]. They comprise the most frequent type of glioneuronal tumors (38.5%) [10]. Second only to benign cortical malformations, gangliogliomas comprise 37-46% of all tumors associated with intractable epilepsy in surgical series. The age at presentation ranges from 2 months to 70 years, with a mean/median age from 8.5 to 25 years. There is a slight male to female predominance (1.1-1.9 to 1) [1,11-14]. Dysplastic gangliocytomas of the cerebellum are too rare to permit demographic characterization [1].

Location and presentation

Gangliocytomas and gangliogliomas predominantly arise in the cerebral hemispheres (up to 70%), but also occur in the cerebellum (15-17%), ventricles (~3%), brainstem (~3%), spinal cord (as low as 2-3%) and extra-axial sites (~1%), such as the optic chiasm or cerebellopontine angle [1,10]. Cerebral tumors predominantly localize to the temporal (40-75%), followed by frontal (12-15), parietal (6-7%) or occipital (~3%) lobes and infrequently multilobar (6-7%). Meningeal or leptomeningeal spread is rarely reported [13,15]. The distinct entity dysplastic gangliocytoma of the cerebellum (Lhermitte-Duclos) strictly arises from the cerebellum, usually confined to a hemisphere, but occasionally multifocal [1].

Clinical symptoms vary depending on location. Given their predilection for temporal and frontal lobes, new onset seizures and refractory epilepsy are their most common presentation. Aside from seizures (50-90%), other common symptoms include increased intracranial pressure (40-50%), cerebellar signs (33%) and focal neurologic deficits (12-15%). Rare symptoms include memory disturbances, cranial nerve palsies and psychiatric symptoms (1-7%) [10]. Dysplastic

OPEN ACCESS

Correspondence:
Yazmín Odia, MD MS, Neuro-Oncology Miami Cancer Institute, Baptist Health South Florida, 8940 N Kendall Drive, Suite 300E Miami FL 33176, USA, Tel: 305-595-2141; Fax: 305-279-7778; E-mail: yazmin.odia@gmail.com

Received Date: *18 May 2016*
Accepted Date*: 08 Jun 2016*
Published Date*: 14 Jun 2016*

Citation:
Odia Y. Gangliocytomas and Gangliogliomas: Review of Clinical, Pathologic and Genetic Features. Clin Oncol. 2016; 1: 1017.

Copyright *© 2016 Yazmin Odia. This is an open access article distributed under the Creative Commons Attribution License, which permits unrestricted use, distribution, and reproduction in any medium, provided the original work is properly cited.*

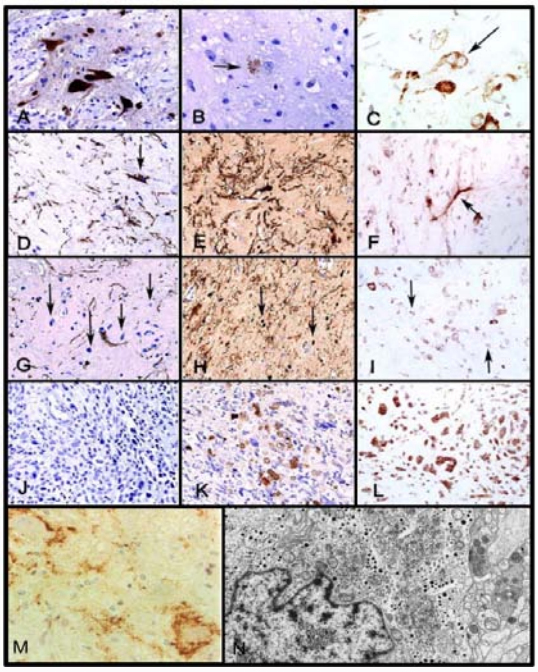

Figure 1: Representative Pathology of Gangliogliomas and Gangliocytomas. The benign component of a lesion contains large NeuN-positive neurons (A, 400×), which occasionally stained for chromogranin (arrow) within the neuronal soma (B, 630×), with some being binucleate and nestin positive (C, arrow, 400×). The large GFAP-positive astrocytes (D, 400×) were also S-100 positive (E, 400×) and nestin positive (F, 400×). Between the large glial and neuronal cells were additional stromal cells with small rounded nuclei (arrows) that did not stain for GFAP (G, 400×) but did stain positive for both S-100 (H) and nestin (I). The malignant component of the tumor was composed of small cells in a loose myxoid stroma and did not stain for GFAP (J, 400×) but demonstrated variable nuclear and cytoplasmic reactivity for S-100 (K, 400×) and strong reactivity for nestin (L, 400×). Immunostaining with antibody to synaptophysin is seen (M). The astrocytes show no staining; some coarse granular immunoreactivity in the neuropil background is present, but there is striking staining along the surfaces of the large neoplastic neurons. This pattern is characteristic of gangliogliomas. Ultrastructure of ganglioglioma: A neuronal cell containing a large number of dense core granules, well developed rough endoplasmic reticulum, and Golgi complexes is shown. Two axonal boutons form synapses with the cell membrane (N, 12, 600x). *Figures reprinted and modified from A Pandita et al, Neuro-Oncology 2007:9(2) (A-L), DC Miller et al, 1993:79 (M) and T Hirose et al, 1996:79(5) (N) with permission from Oxford University Press, JNS Publishing Group, and John Wiley and Sons, respectively.*

gangliocytomas of the cerebellum, as expected, present with cerebellar signs and symptoms of mass effect, including hydrocephalus [1,11].

Imaging findings

On computed tomography (CT), gangliocytomas and gangliogliomas appear as well-circumscribed masses in 80%, with predominant solid (45-50%) or solid cystic (25-30%) features and often a mural nodule (25%) (Figure 1). Focal calcifications are frequent (40-50%), while mass effect and vasogenic edema are found in <10% of cases [10]. Contrast enhancement is also common, though often faint and rarely absent. Scalloping of the adjacent calvarium may occur. Magnetic resonance imaging (MRI) reveals T1 hypointense and T2 hyperintense circumscribed mass lesions, with variable enhancement from none to marked and solid, rim or nodular [16,17]. Dysplastic gangliocytomas of the cerebellum share imaging characteristics, namely solid-cystic features, no or faint enhancement and calcifications. A gyriform 'tiger-striped' appearance in a unilateral cerebellar hemisphere is the hallmark finding on MRI [7]. The relative low cellularity of gangliogliomas correlates with high apparent diffusion coefficient (ADC) values compared to low and high-grade gliomas [18]. Figure 2 depicts typical MRI and head CT findings.

Histopathology

Macroscopically, gangliogliomas are solid or cystic masses. Calcification is common in gross specimens, while hemorrhage and necrosis are rare. Dysplastic gangliocytomas of the cerebellum display discrete regions of hypertrophy and course gyral patterns deep in the cerebellar hemisphere [1].

Microscopically, gangliocytomas are characterized by irregular arrangement of neoplastic ganglion cells, defined as large, multipolar neurons with dysplastic features. The stroma consists of non-neoplastic glial elements, commonly with a dense perivascular reticulin network. Most are at least focally fibrous with collagen staining in the background. Gangliogliomas share the histopathologic findings of gangliocytomas, plus an admixture to varying degrees of neoplastic glial elements. The glial component is typically astrocytic, either fibrillary or pilocytic. Oligodendroglial "fried-egg" or ependymal "perivascular pseudorosettes" patterns are exceedingly rare. Rosenthal fibers and granular bodies are occasionally associated with the astrocytic component. Gangliogliomas are best differentiated from low grade gliomas by four hallmark findings. Clusters of large cells potentially representing neurons are required for diagnosis. Neoplastic glial cells should not cluster around the neoplastic neurons. Fibrosis (desmoplasia) and calcification are the remaining two defining features. Binucleate neurons are diagnostic, but evident in <50% of cases. Lymphocytic or plasma cell infiltrates are common but nonspecific features [4,19].

Anaplastic gangliogliomas typically consist of malignant transformation of the glial component and defined by increased mitotic activity, prominent micro-vascular proliferation, necrosis, and high MIB-1 and TP53 labeling indices, consistent with their WHO grade III classification. Most gangliogliomas have low immunoreactivity for MIB-1 marker of cellular proliferation (mean 1.1 +/- 1.0) and Ki-67 (<1%) labeling indices, consistent with their WHO grade I classification. Anaplastic gangliogliomas, in contrast, have significantly higher MIB-1 (as high as 10.2) and Ki-67 (up to 10%) labeling indices, which have also been correlated with increased size of ganglion cells [11,13,14]. Mitoses are rare in cells with neuronal appearance, [8,11,13,19] while proliferation indices, as denoted by the Ki-67 nuclear antigen, is exclusively found in the astrocytic component. Malignant transformation of both neuronal and glial components remains exceedingly rare [20-22].

The ganglion cells in dysplastic gangliocytomas of the cerebellum causes diffuse enlargement of the molecular and internal granular layers of the cerebellum. The cerebellar architecture is characteristically preserved, with distorted and enlarged but intact folia. Parallel arrays of abnormal myelinated axon bundles are common in the outer molecular layer. Granule neurons can be found under the pia or molecular layer, while Purkinje cells are sparse or absent. Calcification and ecstatic vessels are common, while vacuoles in the molecular layer and white matter are rare [1].

Immunohistochemistry is essential to the accurate diagnosis of gangliocytomas and gangliogliomas. In particular synaptophysin and glial fibrillary acidic protein (GFAP) stains define the relative neuronal and glial components, respectively [19]. Synaptophysin staining along the surface of large neoplastic neurons is characteristic

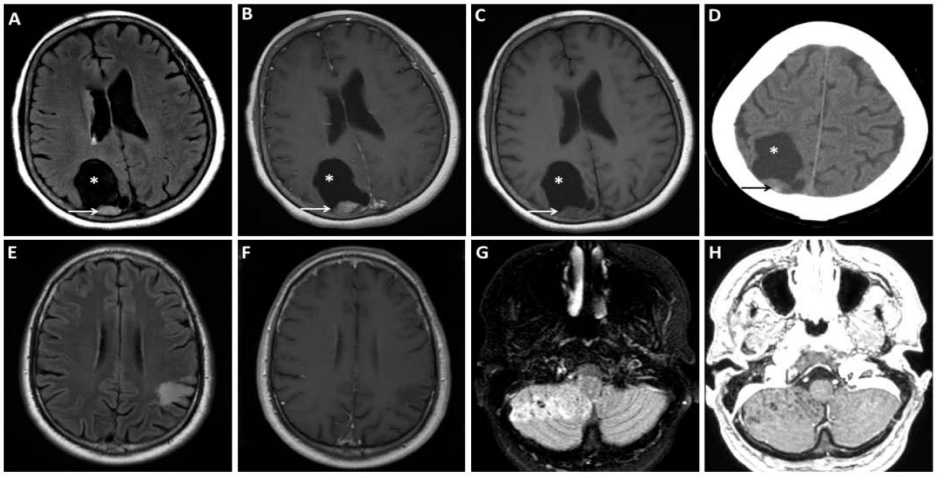

Figure 2: Representative Imaging Findings of Gangliogliomas and Gangliocytomas.
The solid and cystic (*) and enhancing (B-C) and partly calcified (D) mural nodule (arrow) are common findings of gangliogliomas as depicted in T2/FLAIR (A) and post- (B) and pre-gadolinium T1 (C) MRI images and noncontrast head CT (D). Gangliocytomas are also often solid with semi-defined margins with no corresponding enhancement as depicted in T2/FLAIR (E) and post-gadolinium T1 (F) MRI images. Dysplastic gangliocytomas of the cerebellum (Lhermitte-Duclos) have a pathopneumonic MRI appearance of gyriform 'tiger-striped' appearance in a unilateral cerebellar hemisphere (G-H, T2/FLAIR and post-gadolinium T1 MRI, respectively).

of gangliogliomas, but coarse granular immunoreactivity in the neuropil background is also common [19]. Neoplastic neurons also show immunoreactivity for Class 3 betatubulin (100%), neurofilament protein (NFP, 90%), chromogranin A (86%) and S-100 protein (71%), less frequently for vimentin (24%) [11]. Glial cells, in turn, are immunoreactive for GFAP, S-100 protein and vimentin neuroepithelial markers [11]. Microtubule-associated protein-2 (MAP2) immunoreactivity, a hallmark of most low grade glial tumors, is virtually absent in the neoplastic glial component of Gangliogliomas [23].

Ultrastructurally, gangliogliomas show large neuronal cells with cell bodies contacted by numerous neuritic endings containing small clear synaptic vesicles, corresponding to the diagnostic synaptophysin staining pattern. Neuronal cells characteristically contain numerous, dense core granules within the cell body and processes [11]. Spherical protein bodies characteristic for catecholamine neurons in humans have also been reported in select ganglioglioma cases [24]. Distal from the cell bodies, electron microscopy (EM) reveals a dense neuropil of neuritis with microtubules, intermediate filaments and other organelles, but no synaptic endings or dendritic spines. The admixed glial processes are filled with denser filament without parallel microtubules. The glial nuclei are darker with more homogeneous chromatin than neoplastic neuronal nuclei [1,19].

Pathogenesis and Molecular Genetics

One-third of gangliogliomas have chromosomal imbalances, particularly gain of 7 or partial loss of 9q [15,25-27]. Molecular genetic analysis of a ganglioglioma in a toddler with diffused leptomeningeal involvement also revealed loss of chromosome 17p. An abnormal karyotype strongly predicts adverse outcomes [3,15,20].

Mutations in key cell cycle regulators have also been associated with gangliogliomas. Homozygous deletion of 9p21 including the cyclin-dependent kinase inhibitor 2A (*CDKN2A, p16^{Ink4A}*) gene, a tumor suppressor involved in regulating the cell cycle, was detected in 10% of all gangliogliomas and two-thirds of anaplastic Gangliogliomas [28,29]. There is growing evidence suggesting a functional link between *CDKN2A* and *BRAF* genes. Concurrent CDKN2A loss and BRAF activation has been associated with gliomagenesis in mouse models, while the *BRAF-V600E* activating mutation, historically associated with melanoma, colon and papillary thyroid carcinoma, can induce CDKN2A. The *BRAF-V600E* mutation activates the RAS/RAF/MEK/ERK signaling cascade implicated in various malignancies. Not surprisingly, recent studies detected the *BRAF-V600E* mutation in 20-50% of gangliogliomas 20-50%, more frequently in anaplastic (50%) than in WHO grade I (18%) Gangliogliomas [28,29]. Phosphatidylinositol 3-kinases (PI3K) are also vital in cell growth, proliferation, differentiation, motility, survival and intracellular trafficking. While mutations in the PI3K pathway are associated with glioma pathogenesis, no mutations were detected in downstream effectors of the P13K pathway, specifically Ezrin, radixin and moesin (*ERM*) genes in a large series of gangliogliomas. Higher expression of most phosphorylated components of the PI3K/Akt/mTOR pathway, including ERMs, PDK1, mTOR, E-BP1, EIF4G, ribosomal protein S6 kinase phosphorylated at threonine 389 and 229 and ribosomal protein S6, was detected in gangliogliomas when compared to normal cortex [30,31].

While common in gliomas, *IDH1-R132* and *PTEN* mutations as well as *CDK4* and *EGFR* amplification are notably absent in gangliogliomas [31]. The *IDH1-R132* mutation, the hallmark of secondary glioblastomas, was reported in oligodendrogliomas with ganglioglioma-like features (GGLF). With a clinical course more like infiltrative gliomas than gangliogliomas, the GGLF actually reflects neoplastic glial cells with extensive ganglioid differentiation given the frequent 1p19q molecular signature on FISH and *IDH1-R132* immunoreactivity in both glial and ganglioid cells [32]. *TP53* mutations, detected in the majority of gliomas, are only rarely reported in gangliogliomas with local recurrence or transformation to glioblastoma (WHO grade IV) [31,33]. Mutational screening of the *NBN* gene, commonly co-expressed with *TP53* mutations in medulloblastoma, found a single ganglioglioma with a c.511A>g (p.Ile171Val) substitution on one allele of the *NBN* gene. Mutations in the *NBN* (previously named *NBS1*) gene define the Nijmegen breakage syndrome (NBS), a rare autosomal recessive chromosomal instability disorder characterized by microcephaly, dysmorphic

features, immunodeficiency, radiosensitivity and increased risk of cancers. Heterozygous *NBN* mutations are also associated with increased risk of various neoplasms, including melanoma, non-Hodgkin's lymphomas, acute lymphoblastic leukemia, stomach and colorectal cancer, breast and ovarian cancers, rhabdomyosarcoma and medulloblastoma [34].

Cortical architectural abnormalities, including cortical dysplasia and microdysgenesis, are found in 50% of gangliogliomas, near but clearly separate from the tumor. The high incidence of cortical malformations suggests aberrant development as a basis of their pathogenesis [13]. Aberrant overexpression of ERMs effectors of the PI3K pathway is evident in both cortical dysplasia and Gangliogliomas [35]. Analysis of genes in the Reelin signaling cascade involved in neuronal development failed to detect mutations in the cyclin-dependent kinase *CDK5*, doubcortin *DCX*, *p35* and disabled-1, *DAB-1* [36,37]. The *TSC1* and *TSC2* genes also function in cortical differentiation and growth control. Tuberous sclerosis 2 (*TSC2*) alterations, including polymorphisms in intron 4 and exon 41, are overrepresented in patients with gangliogliomas, again suggesting alterations in neuro-developmental signaling cascades [36,38]. *TSC1* and *TSC2* as well as *PTEN* genes have been molecularly linked to the serine-threonine kinase (*LKB1*) gene, a master kinase involved in the control of cell cycle arrest, p53-mediated apoptosis, WNT and TGF-beta signaling, Ras-induced transformation, energy metabolism and cell polarity. Peutz-Jeghers syndrome (PJS), an autosomal dominant disorder, characterized by the benign hamartomatous polyps in the gut and hyper-pigmented macules on the lips and oral mucosa, results from inactivating germline mutations in the *LKB1*. While a few cases of PJS with a germline LKB1 mutation developed a ganglioglioma, no *LKB1* gene mutations have been reported in sporadic Gangliogliomas [39,40].

Various rare genetic syndromes have been associated with aggressive gangliogliomas. A young child with stigmata of neurofibromatosis type 2 (NF2) developed a rapidly growing, exophytic intramedullary ganglioglioma at the cervicomedullary junction. NF2 patients often develop aggressive malignant gliomas, suggesting a causal link between the predilection for the co-occurrence in this single case of the exceedingly rare NF2 syndrome and a ganglioglioma [41]. A woman with Turner Syndrome (TS, monosomy X) developed an anaplastic supratentorial ganglioglioma (WHO grade III). After partial resection and involved field radiation to 60 Gy, a gross total resection of local tumor recurrence revealed transformation to a glioblastoma (WHO grade IV) that resulted in her death 23 months after her initial diagnosis[42]. A child with familial mild learning disability, characterized by congenital cataract and developmental and speech delay, developed a metastatic ganglioglioma with anaplastic transformation by the age of 2 years. Mutational analysis revealed a unique germline 9q34.4 constitutional tandem duplication resulting in breakpoints in intron 1 of *TRAF2* and intron 16 of the *EHMT1* gene. The result is a fusion transcript encoding a truncated form of EHMT1. The ganglioglioma showed complex chromosomal aberrations with further duplication of the dub9q34 [43]. Other microdeletions, duplications and translocations of the 9q32-qter region are associated with various pediatric cases with neurodevelopmental disorders as described by Kleefstra et al. [44]. These cases highlight the significant association between chromosomal instability and gangliogliomas [45].

Cowden syndrome is an autosomal dominant disorder defined by mucocutaneous lesions, specifically multiple trichilemmoma (skin differentiation into the outer root sheath of the hair follicle) and fibromas, as well as systemic malignancies, namely thyroid neoplasms, breast carcinoma and hamartomatous polyps of the colon [1,7]. Cowden syndrome is characterized by germline *PTEN* mutations on chromosome 10q23 in virtually all adult-onset dysplastic gangliocytomas of the cerebellum (Lhermitte-Duclos). Childhood-onset Lhermitte-Duclos lack *PTEN* mutations, suggesting a distinct etiology. In 75% of Lhermitte-Duclos samples, immunohistochemistry reveals complete or partial loss of PTEN expression accompanied by elevated phosphorylated Akt, specifically in the dysplastic gangliocytoma cells. Loss of PTEN function seems sufficient to cause Lhermitte-Duclos as part of Cowden syndrome even without the systemic findings typical of Cowden syndrome [46].

Microarray RNA expression in epilepsy-associated gangliogliomas was compared to postmortem temporal lobe samples from patients with seizure or other neurologic disorders. Microarray results were validated by RT-PCR analysis of 11 selected genes and immunostaining of involved proteins. This microarray analysis yielded numerous target genes, but does not permit precise conclusions of the specific role of these gene expression changes in the pathogenesis or epileptogenicity of gangliogliomas. Specifically, gangliogliomas highly expressed genes involved various in immune and inflammatory responses, including class II histocompatibility antigens, interleukins and their receptors, as well as genes involved in the TGF-beta, Toll-like receptor and T-cell receptor signaling pathways. Both the classical and alternative complement pathways as well as components of the coagulation cascade and iron ion homeostasis were also overexpressed. Synaptic transmission was the most prominent underexpressed process, including voltage gated potassium and calcium channels as well as sodium channel subunits. GABA signaling pathway was downregulated via suppresion of GABA-A receptors and associated proteins as well as increased expression of the sodium-potassium chloride co-transporter (NKCC1), known to modulate the GABA receptor-mediated response. Alterations in these ion and GABA channels may underlie the epileptogenicity of gangliogliomas. Several gene expression changes were specific to gangliogliomas in contrast to other epileptogenic tissues. Genes involved in extracellular matrix and cell adhesion were significantly activated. Additional genes associated with development, cell cycle and Wnt-1/beta-catenin signaling pathway. Genes regulating angiogenesis, including fibroblast growth factors as well as angiopoietin, angiogenin and neuropilin, are prominently overexpressed [47].

Treatment and Clinical Outcomes

Gangliogliomas are typically benign tumors, while less than 5% show WHO grade III pathology. Good prognostic factors include temporal localization, complete surgical resection and long-standing epilepsy [48]. Survival inversely correlates with WHO grade [49]. Based on the SEER registry, median overall survival for anaplastic gangliogliomas is 28.5 months, where only debulking surgery (93%) and extent of disease predict outcome [50]. The 5-year survival rates also differ significantly based on localization, 93%, 84% and 33% for cerebral, spinal cord and brainstem gangliogliomas, respectively. The progression free rates at 5-year are 95% and 36% for cerebral and spinal cord tumors, while only 53% of brainstem gangliogliomas are progression free at 3 years [12,51]. In large surgical series, seizure control is reached in at least 85% of gangliogliomas, up to 96% after gross total but only 54% after subtotal resectionc [52]. Thus, gross total

resection, whenever safe, remains the mainstay and the only curative treatment for gangliogliomas, whether low-grade or malignant [53].

Given the low recurrence rate of low grade gangliogliomas and the unclear benefit of additional treatment after surgical resection, radiation is generally reserved for incompletely resected tumors, especially those with any evidence of malignant features. Yet, based on the SEER registry, only 36% of anaplastic gangliogliomas received adjuvant radiotherapy. The SEER registry analysis revealed no impact of radiotherapy on overall survival [50]. A meta-analysis of 402 gangliogliomas revealed radiation therapy improved local control but failed to impact overall survival in both low and high grade gangliogliomas. Furthermore, the benefit of radiation therapy was only evident after subtotal not gross total resections [53].

Anaplastic change of the glial component predicts a shorter time to recurrence, greater risk of recurrence or malignant transformation, but variably impacts overall survival [8,9,11-13]. Transformation of both glial and neuronal component is exceedingly rare [22]. Transformation to anaplastic (WHO grade III) from low grade gangliogliomas has been reported after incomplete resection and/or decades after involved field radiation. Transformation to glioblastoma (WHO grade IV) is rare and exclusive to partially resected anaplastic gangliogliomas years-to-decades after radiotherapy [42,54]. Only a few cases of anaplastic gangliogliomas unrelated to radiotherapy have been reported [5].

Summary

Gangliocytomas and gangliogliomas are well-circumscribed indolent neuroepithelial tumors. Their prognosis is generally good, even curable with complete resection in the majority of cases. While usually unresectable, dysplastic gangliocytoma of the cerebellum (Lhermitte-Duclos) typically has a benign course. However, they commonly coexist with less favorable multiple hamartoma-neoplasms as part of Cowden syndrome. Primary anaplastic ganglioglioma are rare, while malignant transformation to anaplastic ganglioglioma or glioblastoma often occurs years-to-decades after radiation. Malignant features are almost exclusive to the neoplastic glial rather than ganglion cells. Aggressive features include leptomeningeal dissemination on imaging as well as anaplasia and brisk mitoses on histopathology.

Distinct genetic abnormalities suggest multiple etiologies for this subgroup of glioneuronal tumors. Chromosomal imbalances are evident in a third of gangliogliomas, while *CDKN2A* gene deletion is detected in two-thirds of anaplastic gangliogliomas. Cowden syndrome, an autosomal dominant disorder characterized by germline *PTEN* mutations, defines all adult-onset cases of Lhermitte-Duclos. Other rare genetic syndromes associated with gangliogliomas, particularly with aggressive clinical or pathology features, include NF2, Peutz-Jager and Turner syndromes. Alterations in genes involved in neurodevelopment pathways and the co-existence of cortical architectural abnormalities remote from the primary tumor implicates aberrant cortical development in the pathogenesis of gangliogliomas.

References

1. Louis D, Ohgaki H, Wiestler O, Cavenee W, Burger PC, Jouvet A, et al. WHO Classification of tumours of the central nervous system. Lyon: IARC; 2007.
2. Courville CB. Gangliocytoma myelinicum diffusum of the cerebellar cortex; review of the literature and report of case. Bull Los Angel Neuro Soc. 1958; 23: 72-80.
3. Jay V, Squire J, Blaser S, Hoffman HJ, Hwang P. Intracranial and spinal metastases from a ganglioglioma with unusual cytogenetic abnormalities in a patient with complex partial seizures. Childs Nerv Syst. 1997; 13: 550-555.
4. Blumcke I, Wiestler O. Gangliogliomas: an intriguing tumor entity associated with focal epilepsies. J Neuropathol Exp Neurol. 2002; 61: 575-584.
5. DeMarchi R, Abu-Abed S, Munoz D, Loch Macdonald R. Malignant ganglioglioma: case report and review of literature. J Neurooncol. 2011; 101: 311-318.
6. Lhermitte J, Duclos P. Sur un ganglioneuronme diffus du cortes du cervelet. Bulletin de l'Association française pour l'étude du cancer. 1920; 9: 99-107.
7. Tan T-C, Ho L-C. Lhermitte-Duclos disease associated with Cowden syndrome. J Clin Neurosci. 2007; 14: 801-805.
8. Kalyan Raman UP, Olivero WC. Ganglioglioma: a correlative clinicopathological and radiological study of ten surgically treated cases with follow-up. Neurosurgery. 1987; 20: 428-433.
9. Luyken C, Blümcke I, Fimmers R, Urbach H, Wiestler OD, Schramm J. Supratentorial gangliogliomas: Histopathologic grading and tumor recurrence in 184 patients with a median follow-up of 8 years. Cancer. 2004; 101: 146-155.
10. Chandrashekhar TN, Mahadevan A, Vani S, Yasha TC, Sampath S, Chandramouli BA, et al. Pathological spectrum of neuronal/glioneuronal tumors from a tertiary referral neurological Institute. Neuropathology. 2012; 32: 1-12.
11. Hirose T, Scheithauer BW, Lopes MB, Gerber HA, Altermatt HJ, VandenBerg SR. Ganglioglioma: an ultrastructural and immunohistochemical study. Cancer. 1997; 79: 989-1003.
12. Lang FF, Epstein FJ, Ransohoff J, Allen JC, Wisoff J, Abbott IR, et al. Central nervous system gangliogliomas. J Neurosurg. 1993; 79: 867-873.
13. Prayson RA, Khajavi K, Comair YG. Cortical architectural abnormalities and MIB1 immunoreactivity in gangliogliomas: a study of 60 patients with intracranial tumors. J Neuropathol Exp Neuro. 1995; 54: 513-520.
14. Wolf HK, Mller MB, Spnle M, Zentner J, Schramm J, Wiestler OD. Ganglioglioma: a detailed histopathological and immunohistochemical analysis of 61 cases. Acta Neuropathol. 1994; 88: 166-173.
15. Wacker MR, Cogen PH, Etzell JE, Daneshvar L, Davis RL, Prados MD. Diffuse leptomeningeal involvement by a ganglioglioma in a child. J Neurosurg. 1992; 77: 302-306.
16. Osborn A. Diagnostic Neuroradiology. St. Louis: Mosby; 1994.
17. Grossman R, Yousem D. Neuroradiology. The Requisites. St. Louis: Mosby-Yearbook; 1994.
18. Kikuchi T, Kumabe T, Higano S, Watanabe M, Tominaga T. Minimum apparent diffusion coefficient for the differential diagnosis of ganglioglioma. Neurol Res. 2009; 31: 1102-1107.
19. Miller DC, Lang FF, Epstein FJ. Central nervous system gangliogliomas. J Neurosurg. 1993; 79: 859-866.
20. Jay V, Squire J, Becker LE, Humphreys R. Malignant transformation in a ganglioglioma with anaplastic neuronal and astrocytic components. Report of a case with flow cytometric and cytogenetic analysis. Cancer. 1994; 73: 2862-2868.
21. Kawataki T, Sato E, Sato T, Kinouchi H. Anaplastic Ganglioglioma with malignant features in both neuronal and glial components - A case report. Neurol Med Chir. 2010; 50: 228-231.
22. Mittelbronn M, Schittenhelm J, Lemke D, Ritz R, Nägele T, Weller M, et al.

Low grade ganglioglioma rapidly progressing to a WHO grade IV tumor showing malignant transformation in both astroglial and neuronal cell components. Neuropathology. 2007; 27: 463-467.

23. Blümcke I, Müller S, Buslei R, Riederer BM, Wiestler OD. Microtubule-associated protein-2 immunoreactivity: a useful tool in the differential diagnosis of low-grade neuroepithelial tumors. Acta Neuropathol. 2004; 108: 89-96.

24. Issidorides MR, Havaki S, Chrysanthou-Piterou M, Arvanitis DL. Ultrastructural Identification of Protein Bodies, Cellular Markers of Human Catecholamine Neurons, in a Temporal Lobe Ganglioglioma. Ultrastruct Pathol. 2000; 24: 399-405.

25. Yin X-L, Hui AB-Y, Pang JC-S, Poon WS, Ng H-K. Genome-wide survey for chromosomal imbalances in ganglioglioma using comparative genomic hybridization. Cancer Genet Cytogenet. 2002; 134: 71-76.

26. Bhattacharjee MB, Armstrong DD, Vogel H, Cooley LD. Cytogenetic analysis of 120 primary pediatric brain tumors and literature review. Cancer Genet Cytogenet. 1997; 97: 39-53.

27. Squire JA, Arab S, Marrano P, Bayani J, Karaskova J, Taylor M, et al. Molecular cytogenetic analysis of glial tumors using spectral karyotyping and comparative genomic hybridization. Mol Diagn. 2001; 6: 93-108.

28. Dougherty MJ, Santi M, Brose MS, Ma C, Resnick AC, Sievert AJ, et al. Activating mutations in BRAF characterize a spectrum of pediatric low-grade gliomas. Neuro Oncol. 2010; 12: 621-630.

29. Schindler G, Capper D, Meyer J, Janzarik W, Omran H, Herold-Mende C, et al. Analysis of BRAF V600E mutation in 1,320 nervous system tumors reveals high mutation frequencies in pleomorphic xanthoastrocytoma, ganglioglioma and extra-cerebellar pilocytic astrocytoma. Acta Neuropathol. 2011; 121: 397-405.

30. Boer K, Troost D, Timmermans W, Van Rijen PC, Spliet WGM, Aronica E. Pi3K-mTOR Signaling and AMOG expression in epilepsy-associated glioneuronal tumors. Brain pathol. 2010; 20: 234-244.

31. von Deimling A, Fimmers R, Schmidt MC, Bender B, Fassbender F, Nagel J, et al. Comprehensive allelotype and genetic anaysis of 466 human nervous system tumors. J Neuropathol Exp Neurol. 2000; 59: 544-558.

32. Horbinski C, Kofler J, Yeaney G, Camelo-Piragua S, Venneti S, Louis DN, et al. Isocitrate dehydrogenase 1 analysis differentiates gangliogliomas from infiltrative gliomas. Brain pathol. 2011; 21: 564-574.

33. Hayashi Y, Iwato M, Hasegawa M, Tachibana O, von Deimling A, Yamashita J. Malignant transformation of a gangliocytoma/ganglioglioma into a glioblastoma multiforme: a molecular genetic analysis. J Neurosurg. 2001; 95: 138-142.

34. Grajkowska W, Piekutowska-Abramczuk D, Ciara E, Dembowska-Baginska B, Perek D, Roszkowski M, et al. Ganglioglioma associated with alterations of NBN gene. A case report. Folia Neuropathol. 2009; 47: 278-283.

35. Majores M, Schick V, Engels G, Fassunke J, Elger CE, Schramm J, et al. Mutational and immunohistochemical analysis of ezrin-, radixin-, moesin (ERM) molecules in epilepsy-associated glioneuronal lesions. Acta Neuropathol. 2005; 110: 537-546.

36. Becker AJ, Löbach M, Klein H, Normann S, Nöthen MM, von Deimling A, et al. Mutational analysis of TSC1 and TSC2 genes in gangliogliomas. Neuropathol Applied Neurobiol. 2001; 27: 105-114.

37. Kam R, Chen J, Blümcke I, Normann S, Fassunke J, Elger CE, et al. The reelin pathway components disabled-1 and p35 in gangliogliomas – a mutation and expression analysis. Neuropathol Appl Neurobiol. 2004; 30: 225-232.

38. Parry L, Maynard J, Patel A, Hodges AK, von Deimling A, Sampson JR, et al. Molecular analysis of the TSC1 and TSC2 tumour suppressor genes in sporadic glial and glioneuronal tumours. Human Genetics. 2000; 107: 350-356.

39. De Tommasi A, Luzzi S, D'Urso PI, De Tommasi C, Resta N, Ciappetta P. Molecular genetic analysis in a case of ganglioglioma: identification of a new mutation. Neurosurgery. 2008; 63: 976-980.

40. Resta N, Lauriola L, Puca A, Susca FC, Albanese A, Sabatino G, et al. Ganglioglioma arising in a Peutz-Jeghers patient: a case report with molecular implications. Acta Neuropathol. 2006; 112: 106-111.

41. Sawin PD, Theodore N, Rekate HL. Spinal cord ganglioglioma in a child with neurofibromatosis type 2. Case report and literature review. J Neurosurg. 1999; 90: 231-233.

42. Naydenov E, Tzekov C, Minkin K, Nachev S. Malignant progression of anaplastic supratentorial ganglioglioma into glioblastoma multiforme in a patient with turner syndrome. J Neurol Surg A Cent Eur Neurosug. 2012; 73: 253-255.

43. Cheung HC, Yatsenko SA, Kadapakkam M, Legay H, Su J, Lupski JR, et al. Constitutional tandem duplication of 9q34 that truncates EHMT1 in a child with ganglioglioma. Pediatr Blood Cancer. 2012; 58: 801-805.

44. Kleefstra T, van Zelst-Stams WA, Nillesen WM, Cormier-Daire V, Houge G, Foulds N, et al. Further clinical and molecular delineation of the 9q subtelomeric deletion syndrome supports a major contribution of EHMT1 haploinsufficiency to the core phenotype. J Med Genet. 2009; 46: 598-606.

45. Yatsenko SA, Brundage EK, Roney EK, Cheung SW, Chinault AC, Lupski JR. Molecular mechanisms for subtelomeric rearrangements associated with the 9q34.3 microdeletion syndrome. Hum Mol Genet. 2009; 18: 1924-1936.

46. Zhou X-P, Marsh DJ, Morrison CD, Chaudhury AR, Maxwell M, Reifenberger G, et al. Germline Inactivation of PTEN and Dysregulation of the Phosphoinositol-3-Kinase/Akt Pathway Cause Human Lhermitte-Duclos Disease in Adults. Am J Hum Genet. 2003; 73: 1191-1198.

47. Aronica E, Boer K, Becker A, Redeker S, Spliet WG, van Rijen PC, et al. Gene expression profile analysis of epilepsy-associated gangliogliomas. Neuroscience. 2008; 151: 272-292.

48. Khashab ME, Gargan L, Margraf L, Koral K, Nejat F, Swift D, et al. Predictors of tumor progression among children with gangliogliomas. J Neurosurg Pediatr. 2009; 3: 461-466.

49. Majores M, von Lehe M, Fassunke J, Schramm J, Becker AJ, Simon M. Tumor recurrence and malignant progression of gangliogliomas. Cancer. 2008; 113: 3355-3363.

50. Selvanathan S, Hammouche S, Salminen H, Jenkinson M. Outcome and prognostic features in anaplastic ganglioglioma: analysis of cases from the SEER database. J Neurooncol. 2011; 105: 539-545.

51. Luyken C, Blümcke I, Fimmers R, Urbach H, Elger CE, Wiestler OD, et al. The Spectrum of Long-term Epilepsy–associated Tumors: long-term seizure and tumor outcome and neurosurgical aspects. Epilepsia. 2003; 44: 822-830.

52. Southwell DG, Garcia PA, Berger MS, Barbaro NM, Chang EF. Long-term seizure control outcomes after resection of gangliogliomas. Neurosurgery. 2012; 70: 1406-1414.

53. Rades D, Zwick L, Leppert J, Bonsanto MM, Tronnier V, Dunst J, et al. The role of postoperative radiotherapy for the treatment of gangliogliomas. Cancer. 2010; 116: 432-442.

54. Lee C-C, Wang W-H, Lin C-F, Chen H-H, Chen S-C, Lin S-C, et al. Malignant transformation of supratentorial ganglioglioma. Clinical Neurology and Neurosurg. 2012; 114: 1338-1342.